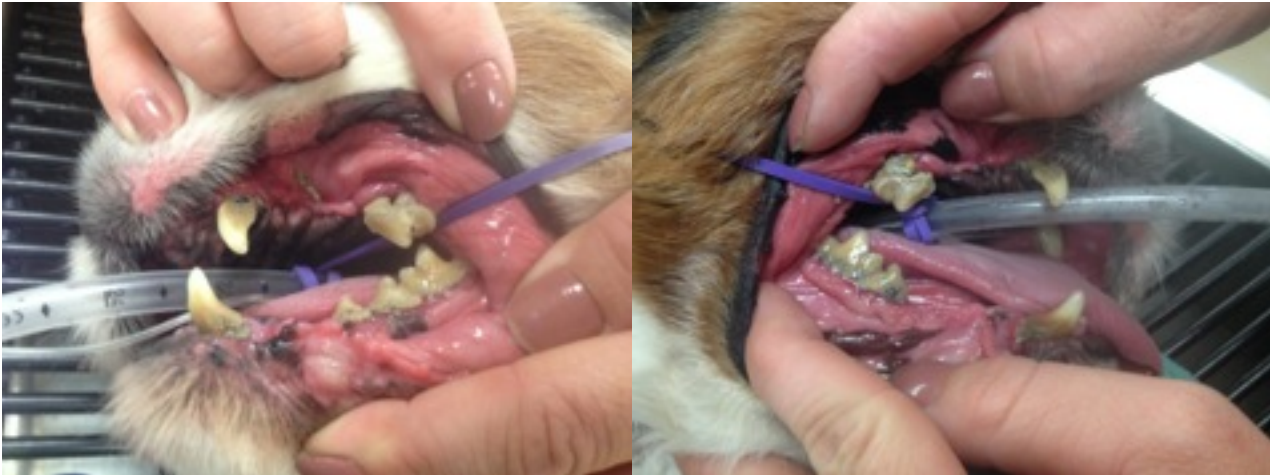
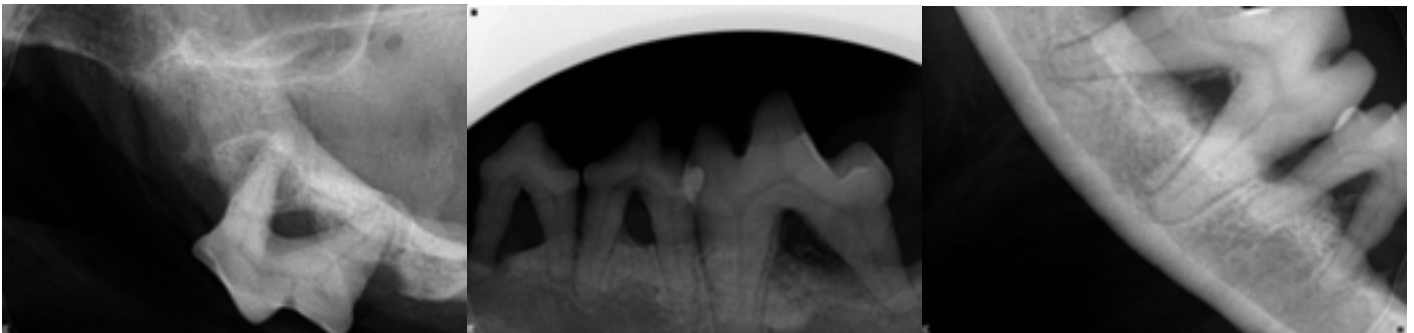


## Dental Case Presentation

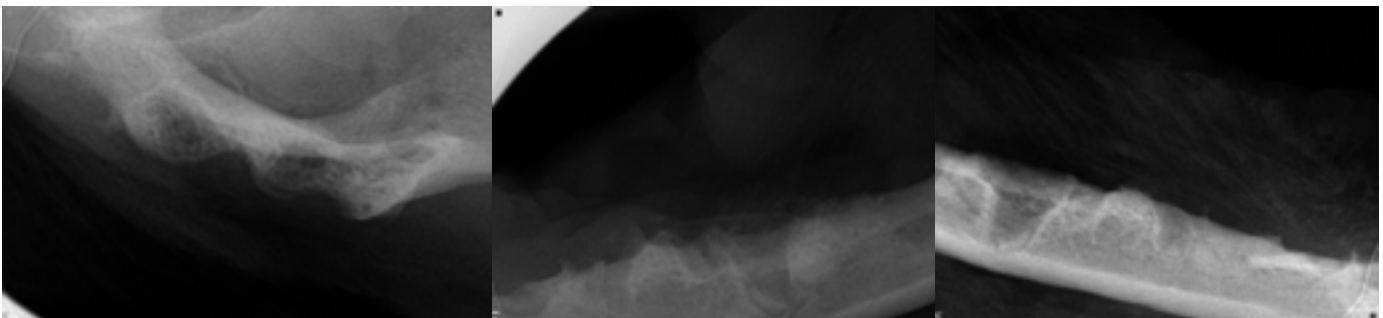
Leo is an 11 year old Cavalier King Charles Spaniel that had an dental cleaning procedure earlier this month. His owners noticed that his breath had began to smell and he was painful on oral palpation. These are his pre-dental cleaning pictures. It is apparent that Leo has accumulated a lot of plaque and calculus causing pain and inflammation of his mouth.



We take dental radiographs of every single patient under anesthesia for a dental procedure. In Leo's case, dental radiographs showed multiple areas of extensive bone loss surrounding each tooth. These teeth are loose and have root exposure, causing pain throughout Leo's mouth. We decided that to extract the affected teeth would be the best option for Leo. The diseased teeth are the source of pain, inflammation and infection in Leo's mouth.



Post-extraction radiographs confirm that no dental roots were left during the oral surgery.



At the one week post-surgery visit, Leo was doing great! He was out of pain and feeling much better than before. He was having no problem eating food and was ready to begin transitioning back to hard food, which he'll have no problems eating now!